

## A Vanishing Tumor in the Right Pulmonary Apex: A Ghost on the Roof

Daiki Akagaki,<sup>1</sup> Toyoharu Oba,<sup>1\*</sup> Masaharu Nakano,<sup>1</sup> Takaharu Nakayoshi,<sup>1</sup> Go Haraguchi,<sup>1</sup> Aya Ohbuchi,<sup>1</sup> Hideki Ohshima,<sup>1</sup> Michihide Nishihara,<sup>1</sup> and Yoshihiro Fukumoto<sup>1</sup>

<sup>1</sup>Division of Cardiovascular Medicine, Department of Internal Medicine, Kurume University School of Medicine, Kurume, Japan

\*Corresponding author: Toyoharu Oba, Division of Cardiovascular Medicine, Department of Internal Medicine, Kurume University School of Medicine, 67 Asahi-machi, Kurume, Japan. Tel: +81-942317562, Fax: +81-942336509, E-mail: ohba\_toyoharu@kurume-u.ac.jp

Received 2015 June 1; Revised 2015 July 15; Accepted 2015 August 15.

### Abstract

**Introduction:** In patients with acute heart failure, pleural fluid localized in an inter-pleural fissure produces a mass on chest X-ray, which mimics a tumor.

**Case Presentation:** Such masses have been designated as vanishing tumors of the lung. It is extremely rare that a vanishing tumor occurs in the apex of the lung.

**Conclusions:** This is the first case report of a vanishing tumor in the right pulmonary apex.

**Keywords:** Vanishing Tumor, Heart Failure, X-ray

### 1. Introduction

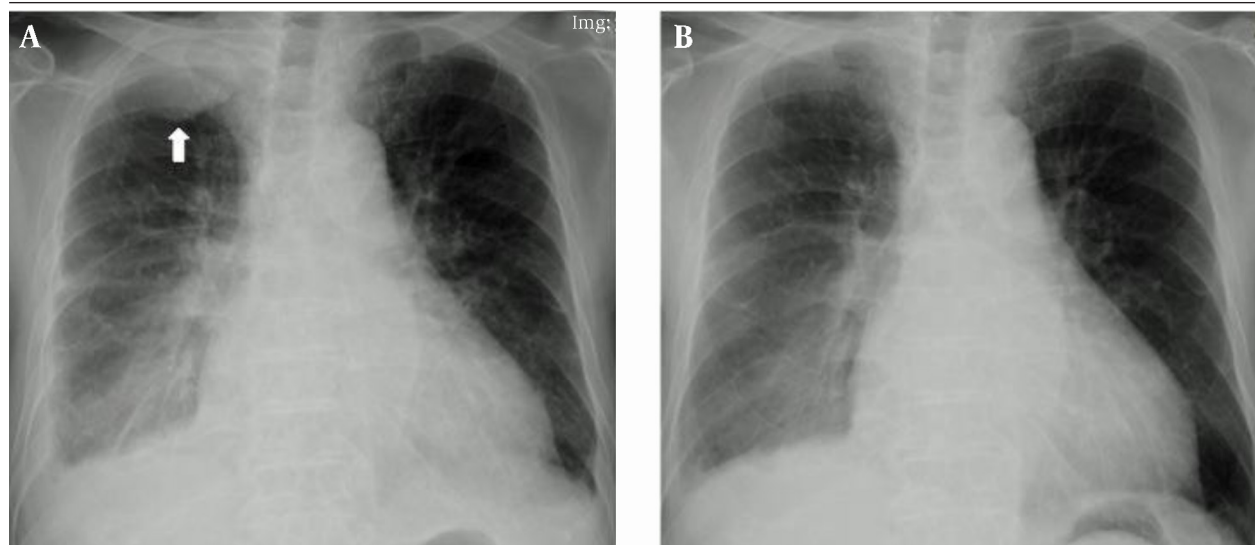
In patients with acute heart failure, pleural fluid localized in an inter-pleural fissure produces a mass on chest X-ray, which mimics a tumor. Diagnosis is normally confirmed by demonstrating the disappearance of the mass following heart failure treatment. As the disorder is not rare at all, such masses have been designated as vanishing tumors of the lung.

### 2. Case Presentation

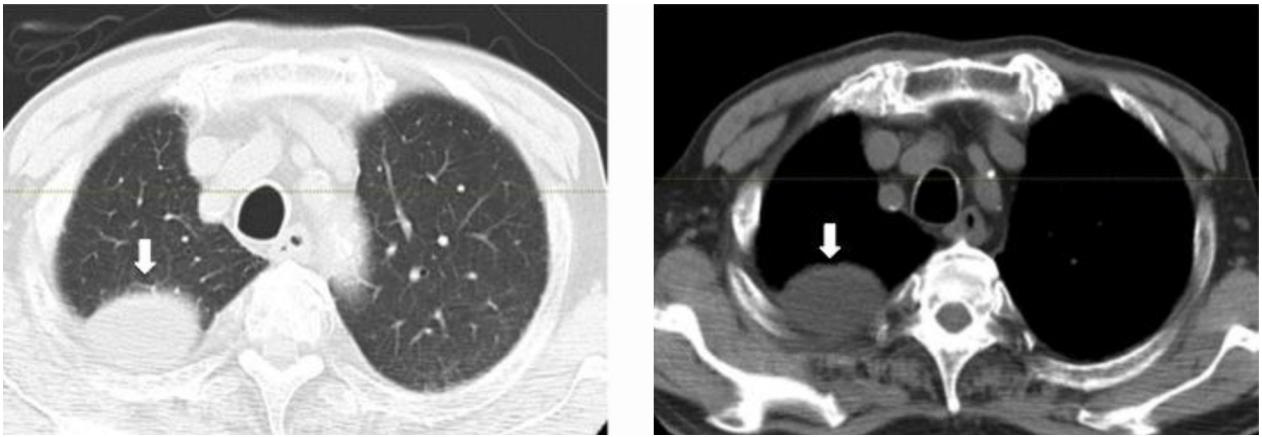
A 88-year-old man with hypertension, chronic kidney

disease and dyslipidemia was admitted to our hospital due to acute heart failure. Chest X-ray and computed tomography scan showed a mass in the apex of the right lung (Figure 1A and Figure 2, white arrows). His symptoms disappeared in a few days after standard treatment of the heart failure. In the chest X-ray after recovering from heart failure, the mass in the apex of the right lung was completely disappeared (Figure 1B). As a result, the mass in the apex of the right lung was diagnosed as pleural fluid.

Figure 1. Chest X-ray



A, A tumor in the apex of the right lung at admission; B, vanished tumor after treatment for acute heart failure.



**Figure 2.** Thoracic Computed Tomography Scan at Admission Shows a Tumor in the Apex of the Right Lung

### 3. Discussion

The lung vanishing tumors are phantom or pseudo tumor, which are localized inter-lobar effusions in the setting of heart failure and vanish after appropriate treatment. In the clinical settings, vanishing tumors are commonly found within the minor fissure, but less frequently within the major fissure (1, 2). Pleural fluid, as well as vanishing tumors, observed in patients with acute heart failure is predominantly right-sided (3). The vanishing tumor usually occurs in transverse fissure between the right upper and middle lobes, as previously reported (4). Therefore, it is extremely rare that a vanishing tumor occurs in the apex of the lung. To the best of our knowledge, this is the first case report of a vanishing tumor in the right pulmonary apex.

### Footnote

**Authors' Contribution:** Daiki Akagaki was a chief phy-

sician of this case. Masaharu Nakano, Takaharu Nakayoshi, Go haraguchi and Aya ohbuchi were a coworker of Daiki Akagaki. Toyoharu Oba developed the original idea, wrote the manuscript, and was a guarantor. Yoshihiro Fukumoto, Hideki Ohshima and Michihide Nishihara contributed to prepare the manuscript.

### References

1. Alderisio WG. Images in cardiovascular medicine. Vanishing tumor. *Circulation*. 2007;**115**(13):e381-2. doi: 10.1161/CIRCULATIONAHA.106.672048. [PubMed: 17404166]
2. Ardic I, Yarlioglu M, Celik A, Kaya MG. Vanishing or phantom tumor of the lung. *Tex Heart Inst J*. 2010;**37**(6):730-1. [PubMed: 21224960]
3. The Preponderance of Right Hydrothorax in Congestive Heart Failure. *Ann Intern Med*. 1946;**25**(6):916. doi: 10.7326/0003-4819-25-6-916. [PubMed: 20277497]
4. Geftter WI, Boucot KR, Marshall EW. Localized interlobar effusion in congestive heart failure; Vanishing tumor of the lung. *Circulation*. 1950;**2**(3):336-43. [PubMed: 15434934]